

Swing From The Hip: An Unusual Cause Of Recurrent Hip Pain In A High School Softball Player

Stephen H. Luebbert, MD; Brian W. Toedebusch, MD

University of Missouri Department of Physical Medicine and Rehabilitation



School of Medicine
University of Missouri

Case History

- A 14-year-old female competitive high school softball player presented to a sports medicine clinic with a 1-week history of acute left hip pain.
- The patient's past medical history included scoliosis but was otherwise negative with no prior surgeries, procedures, or prior hip injury or pain.
- She injured her left hip mid-swing and felt a pop in her hip with immediate anterior groin pain, needing assistance to exit the field.
- After a week of rest, pain improved and she attempted to return to sport.
- Her pain returned, and athletic trainer referred her for evaluation.
- She could bear weight, but had pain with walking and climbing stairs.
- The pain centered over the left anterior hip, was non-migratory, and had no associated paresthesia or weakness.

Initial Physical Exam

- Height: 168 cm Weight: 53.8 kg BMI: 19.1
- General physical exam unremarkable.
- Musculoskeletal: Minimally antalgic gait.
- Slight tenderness to palpation along left hip flexor.
- No pubic or greater trochanteric tenderness.
- Passive range of motion of left hip was 100 degrees of flexion, 60 degrees of external rotation, 20 degrees of internal rotation.
- Strength 5/5 with left hip flexion, left hip abduction, left hip adduction, knee extension, and knee flexion.
- Negative hip flexion, abduction, and external rotation (FABER) and hip flexion, adduction, and internal rotation (FADIR).

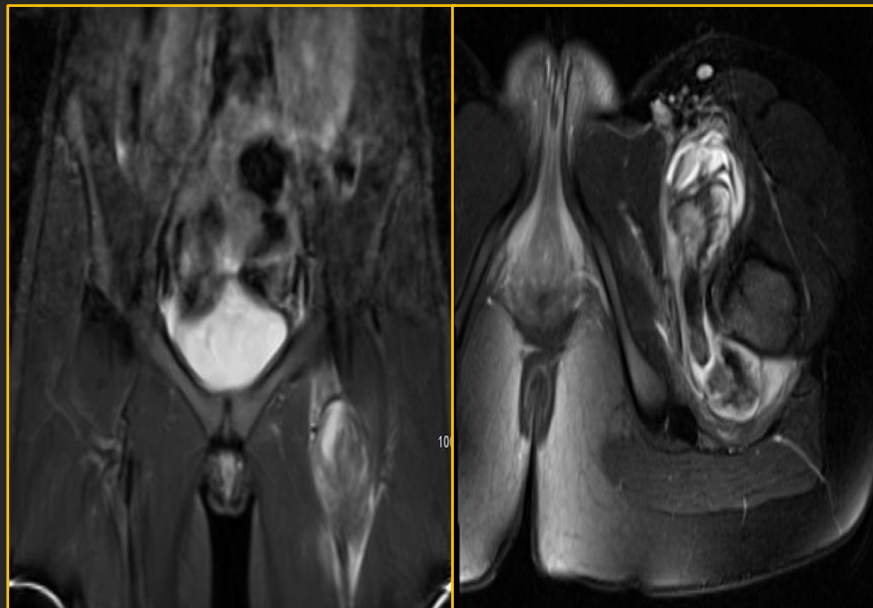
Initial Management and Follow Up

- X-ray showed no remarkable findings. Pain was originally contributed to left hip flexor strain, ordered physical therapy (PT) and rest from sport for 2 weeks. Upon follow up, symptoms were refractory despite rest and PT. Magnetic resonance imaging (MRI) of her hip was ordered.

Differential Diagnosis

- Iliopsoas strain
- Hip labral tear/dysplasia
- Femoral neck stress fracture
- Transient synovitis of hip
- Intramuscular hematoma

Imaging Studies



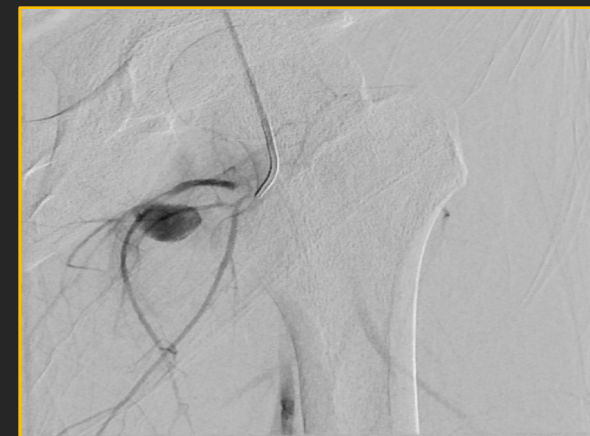- A large, heterogeneous dumbbell-shaped mass identified at the myotendinous junction of the iliopsoas muscle. Large hematoma associated with grade 2 iliopsoas tear is most likely etiology. Iliopsoas tendon intact.

Follow Up and Treatment

- Hip pain became recalcitrant to PT, analgesic, and muscle relaxer.
- Follow up MRI obtained one month later for refractory pain revealed increase in hematoma. Orthopedic oncology consulted due to concern of possible mass versus hematoma.
- Complete blood count and coagulation studies ordered for hematoma enlargement, but were unremarkable.
- Interventional radiology consulted for placement of drain with tissue plasminogen activator (tPA).
- Patient became syncopal and required hospitalization.
- Angiography identified medial profunda femoris artery pseudoaneurysm and was treated by embolization.

Final Diagnosis

Recurrent left hip hematoma secondary to medial profunda femoris artery pseudoaneurysm



Return to Play

- One week after embolization, the patient was pain-free and able to start light workouts in gym class.
- She gradually returned to batting, with no high-impact activity over three weeks.
- After safe demonstration of her sport-specific tasks with physical therapy, the patient returned to full play without restrictions.

Discussion

- Pseudoaneurysms are local hematomas contained by less than all three arterial layers (tunica intima, media, and externa).
- Profunda femoris pseudoaneurysms can often be from infection, trauma, vascular access, or surgery.
- As the pseudoaneurysm grows, groin swelling, pulsatile masses, and hip pain can occur. Profunda femoris artery traction may have occurred with her iliopsoas tear.
- This report is unique due to the paucity of literature of profunda femoris pathology in the absence of femoral fracture, especially in pediatrics.
- Long-term treatment options include coil embolization, US-guided decompression, thrombin injection, or open surgical repair.