



Image of the Month

Image of the Month

April 6, 2016 [Image of the Month](#)

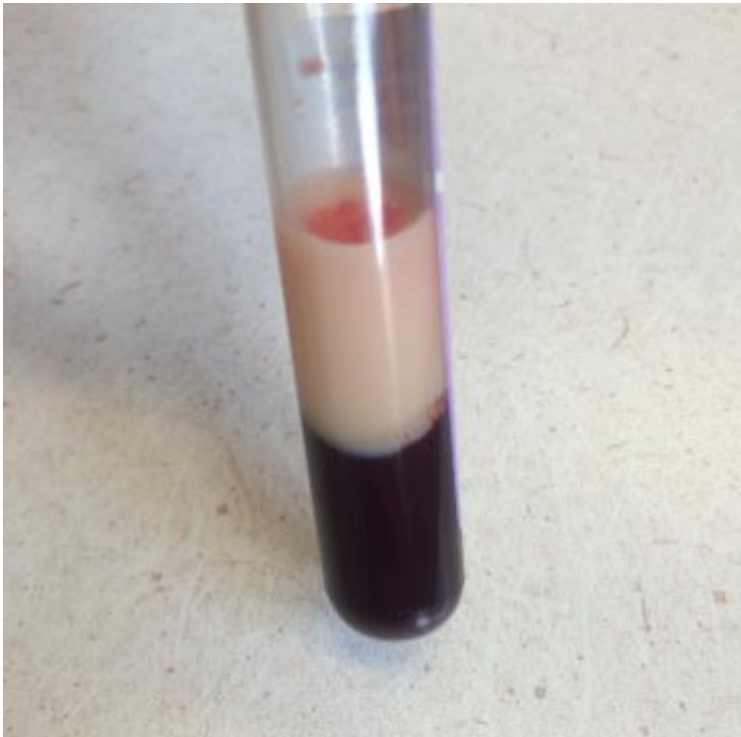
Keywords [pancreatitis](#)

Image of the Month

Luke Andrea, MS3; Christian Rojas-Moreno, MD

University of Missouri School of Medicine, Columbia, MO

A 24 year old man presented to the emergency department with a one day history of abdominal pain. The pain was sudden in onset, 8/10 in severity, and radiated to the back. There was associated nausea but no vomiting. He reported experiencing this type of pain twice in the past. When asked about his past medical history the patient stated he may have been diagnosed with diabetes. He reported heavy drinking between the ages of 19 and 21 but has not had a drink since. Vitals included – temperature 36.3 C (97.3 F), blood pressure 144/83 mmHg, pulse 91/minute, and respirations 18/minute. There was tenderness on palpation throughout the epigastric region but no rigidity or guarding. Laboratory results on admission showed leukocytosis and a fingerstick glucose of 334 mg/dL. After ordering a complete metabolic profile, the patient's nurse called and reported that a tube of blood which had been drawn had the following appearance:



What is the most likely diagnosis in this patient?

1. Bacterial pneumonia
2. Large bowel obstruction
3. Cholecystitis
4. Pancreatitis

5. Peptic ulcer disease

ANSWER

This patient has pancreatitis resulting from hypertriglyceridemia. The epigastric pain which radiates to his back places pancreatitis high on the differential diagnosis. Leukocytosis with elevated amylase and lipase levels would have helped finalize a diagnosis of pancreatitis [1], but these lab results were not provided. The question instead shows a tube of lipemic blood where the lipids have separated to form the top fraction. This finding is consistent with hypertriglyceridemia [2], and makes pancreatitis caused by elevated triglycerides the most likely diagnosis.

PATIENT CASE

This 24 year old man presented to the emergency department after 24 hours of severe abdominal pain described in the above vignette and he was admitted for acute pancreatitis. Labs on admission showed lipase of 199 units/L (ref: 13-60), sodium of 126 mmol/L (ref: 136-145), cholesterol of 634 mg/dL (ref: 140-200), and hemoglobin A1C of 13.7% (ref: 4-6). Several other lab values including albumin, bilirubin, AST, ALT, and triglycerides were not measurable by the hospital lab due to the triglyceride content of the patient's blood, and were reported as lipemic. The image above is an actual sample from the patient. He did not have any of the physical exam manifestations of severely elevated lipids such as tendon xanthomas, xanthelasmas, or corneal arcus.

A CT scan of the abdomen confirmed the diagnosis of acute pancreatitis and also showed hepatic steatosis. The patient was treated with intravenous fluids, narcotics for pain control, and a titrated insulin drip for his elevated triglycerides and blood glucose. He was also started on gemfibrozil. The first detectable triglyceride level in the patient was after two days of insulin therapy, and was read at 1638 mg/dL (ref: 0-200), eventually coming down to 480 mg/dL. He was discharged a few days later in a stable medical condition.

DISCUSSION

Hypertriglyceridemia is implicated in 1% to 7% of all cases of pancreatitis, and is the most common cause of acute pancreatitis outside of gallstones and alcohol [3]. It is even more common during pregnancy, causing up to 56% of pancreatitis cases. Hypertriglyceridemia is defined as levels greater than 150 gm/dL. Triglyceride elevations above 1000 mg/dL confer the risk of pancreatitis, although many patients do not begin to show symptoms until levels are greater than 4000 mg/dL [4]. For levels to rise over 1800 mg/dL, there is often an underlying genetic defect in lipid metabolism. Mild to moderate elevated triglycerides may also be a finding in pancreatitis of any etiology, with levels between 175 mg/dL and 900 mg/dL occurring in nearly 50% of patients with acute pancreatitis [5].

Triglycerides and free fatty acids have been shown to damage pancreatic tissue in experimental models, although the pathogenesis of hypertriglyceridemia induced pancreatitis has not been fully elucidated. Chylomicrons are thought to be responsible for the majority of inflammation. They are lipoproteins composed of 90% triglycerides, and can be found in the blood when triglyceride levels are at or above 900 mg/dL [6]. Chylomicrons are thought to damage the pancreas in several ways. Pancreatic lipases degrade chylomicrons and triglycerides into pro-inflammatory non-esterified free fatty acids which may destroy pancreatic vasculature and pancreatic cells. This lipotoxicity results in even further release of inflammatory byproducts and enzymes by damaged pancreatic tissue [7-9]. Chylomicrons are large lipoproteins, ranging from 75 to 600 nm in diameter, and may block pancreatic microvasculature which would damage cells and result in inflammation and pancreatic enzyme release.

Hypertriglyceridemia induced pancreatitis must be treated the same way pancreatitis from any other cause is treated, including pain control and aggressive hydration. The goal for treatment is achieving triglyceride levels of less than 500 mg/dL [10]. Therapeutic plasma exchange, can treat hypertriglyceridemia induced pancreatitis in emergent situations and is only recommended when the triglycerides are elevated above 1000 mg/dL, lipase levels are elevated more than three times the upper limit of normal, and there are signs or symptoms of systemic inflammatory response or organ failure such as hypocalcemia, lactic acidosis, or organ dysfunction [11]. Finally, fibrates are first line for reducing triglycerides. They have significant interactions with statins, increasing the risk of myopathy and rhabdomyolysis, so caution must be taken when combining the two.

REFERENCES

- 1 Whitcomb DC. Acute Pancreatitis. 2006; 354:2142-2150.
- 2 Berglund L, Brunzell JC, Goldberg AC, Goldberg IJ, Sacks F, Murad MH, Stalenhoef AFH. Evaluation and Treatment of Hypertriglyceridemia: An Endocrine Society Clinical Practice Guideline. . 2012 Sep; 97(9): 2969–2989.
- 3 Searles GE, Ooi TC. Underrecognition of chylomicronemia as a cause of acute pancreatitis. 1992; 147: 1806-1808.
- 4 Athyros VG, Giouleme OI, Nikolaidis NL, Vasiliadis TV, Bouloukos VI, Kontopoulos AG, et al. Long-term follow-up of patients with acute hypertriglyceridemia-induced pancreatitis. . 2002 Apr. 34(4):472-5.
- 5 Dominguez-Munoz JE, Malfertheiner P, Ditschuneit HH, Blanco-Chavez J, Uhl W, Buchler M, Ditschuneit H. Hyperlipidemia in acute pancreatitis. Relationship with etiology, onset, and severity of the disease. Int J Pancreatol 1991; 10: 261-267.
- 6 Gan SI, Edwards AL, Symonds CJ, Beck PL. Hypertriglyceridemia-induced pancreatitis: A case-based review. 2006; 12(44): 7197-7202.
- 7 Yang F, Wang Y, Sternfeld L, Rodriguez JA, Ross C, Hayden MR, Carriere F, Liu G, Schulz I. The role of free fatty acids, pancreatic lipase and Ca⁺ signalling in injury of isolated acinar cells and pancreatitis model in lipoprotein lipase-deficient mice. . 2009 Jan;195(1):13-28.
- 8 Kimura W, Mössner J. Role of hypertriglyceridemia in the pathogenesis of experimental acute pancreatitis in rats. . 1996; 20(3):177-184.
- 9 Pejic RN, Lee DT. Hypertriglyceridemia. May-June 2006; 19(3):310-316.
- 10 Scherer J, Singh VP, Pitchumoni CS, Yadav D. Issues in hypertriglyceridemic pancreatitis: an update. . 2014; 48(3):195-204.
- 11 Lennertz A, Parhofer KG, Samtleben W, Bosch T. Therapeutic plasma exchange in patients with chylomicronemia syndrome complicated by acute pancreatitis. . 1999; 3(3):227.