



Disguised as Encephalitis; Atypical Presentation of Severe Chiari Malformation Shows Immediate Functional Improvement Following Surgical Decompression: A Case Report.



Rachael N. Brashears DO, MBA; Jane Anne Emerson, MD; and Tomoko Tanaka, MD
Department of Physical Medicine and Rehabilitation and Department of Neurosurgery
University of Missouri Healthcare, Columbia, MO

Case Description

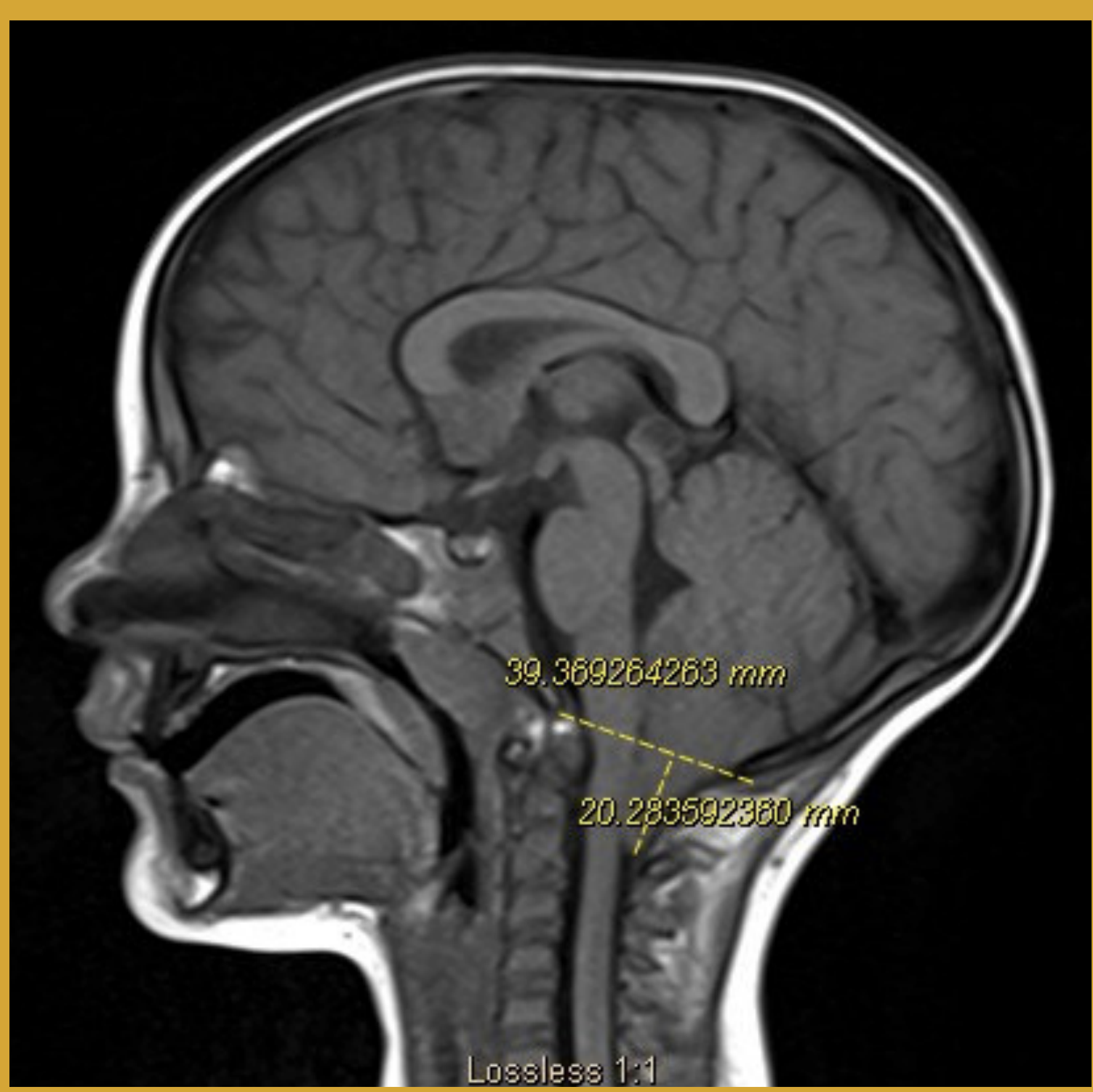- A previously healthy 3 year-old female presented with three day history of fever, lethargy, and ataxia, without headache.
- She subsequently developed seizures, dysarthria, dysphagia, and weakness.
- Workup revealed:
 - normal EEG, drug/toxin screen, chest X-ray, CT head, and MRI spine.
 - Lumbar puncture was unremarkable and CSF PCR was initially negative.
 - Respiratory panel was positive for Adenovirus.
- She was treated empirically for meningitis/encephalitis with Acyclovir, Ceftriaxone, and Vancomycin without improvement in symptoms.
- Infectious disease was consulted and recommended to:
 - Discontinue current abx as work up had been negative.
 - Start a 10 day course of doxycycline for possible tickborne illness.
- Pediatric neurology was consulted and stated it is likely a post infectious encephalitis.
- MRI brain was negative for acute encephalitis or hydrocephalus but did reveal a Chiari malformation with herniation of cerebellar tonsils extending 20 mm below the foramen magnum.
- MRI cervical, thoracic, and lumbar spine were normal and negative for syringomyelia or transverse myelitis.
- Surgery was initially postponed due to concerns of acute infection.
- While on rehabilitation, patient's fever resolved but she developed incontinence with worsening ataxia and dysarthria.
- A CSF flow study revealed obstruction in cerebellar CSF flow.
- Neurosurgery was consulted for surgical evaluation.
- Urgent neurosurgical decompression resulted in immediate symptom improvement.

Results

- 17 days after presentation:
 - Patient underwent a suboccipital craniectomy with C1 and partial C2 laminectomy for decompression of Chiari malformation.
- Post op day 1:
 - Patient showed dramatic improvement in her ataxia, dysarthria, and mobility.
- 25 days after presentation:
 - Patient continued to improve with her therapies and was discharged to home with her mother in stable and improved condition

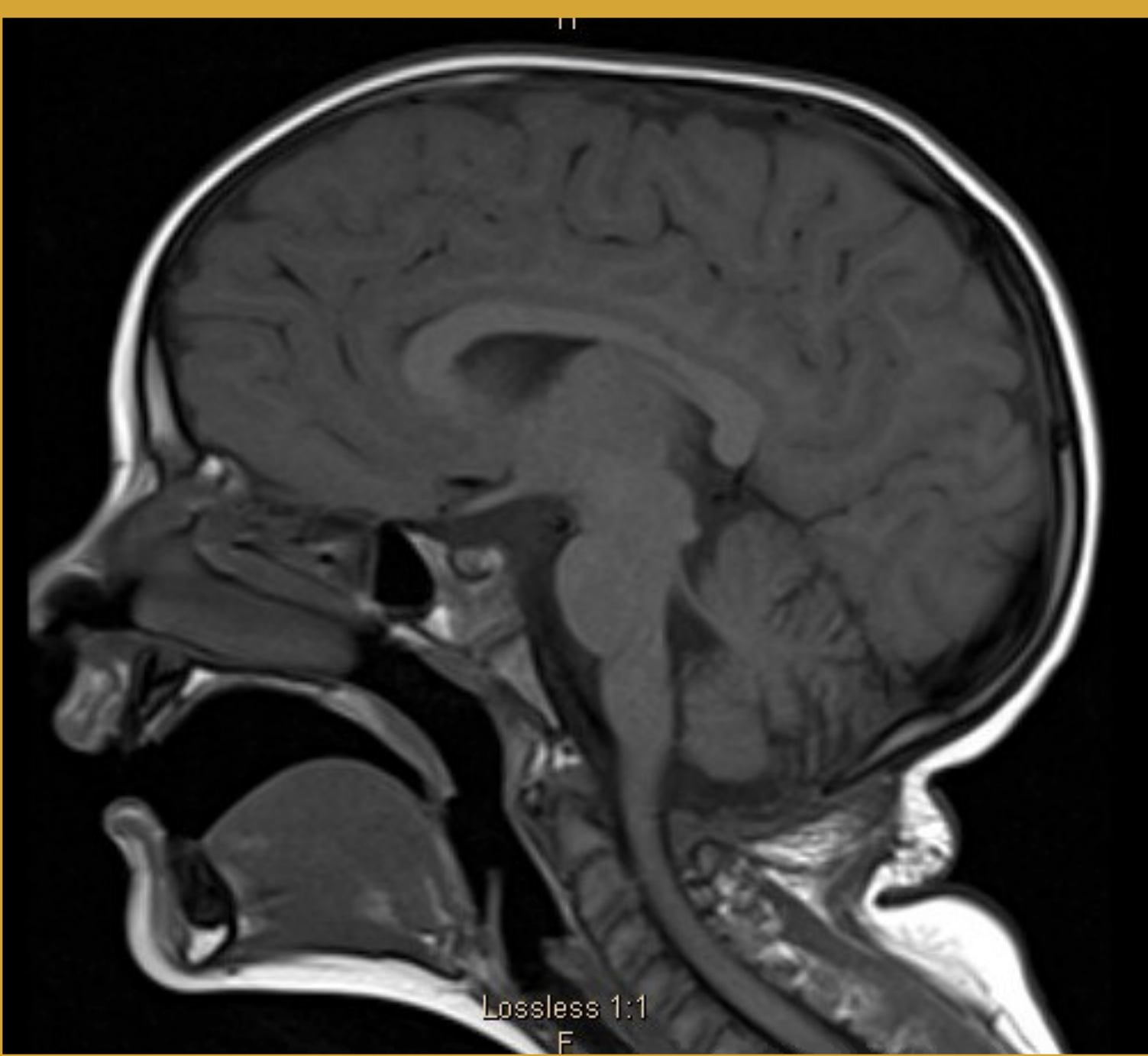
Pre-Op Brain MRI:

Cerebellar tonsils extend 20 mm below the foramen magnum causing crowding at craniocervical junction.



Post-Op Brain MRI:

Suboccipital posterior decompression and the cerebellar tonsils do not extend below the foramen magnum. Moderate volume loss of the cerebellum.



Functional Changes

| Activity | Pre-Op Functioning | Post-Op Functioning | Discharge Functioning |
|-------------------------------|---|---|--|
| Seated Balance | Max Assist | Stand by Assist No loss of balance | Independent |
| Standing Balance | Mod Assist | Stand by Assist No loss of balance | Independent |
| Supine to Sit | Mod Assist to Dependent | Stand by Assist | Stand by Assist |
| Sit to Stand | Mod Assist to Dependent | Stand by Assist to Min Assist Hyperextends lower extremity for stability | Stand by Assist |
| Ambulation | 3 ft x 4 at Mod to Max Assist | 225 ft at Min to Mod Assist | >300ft at Stand By Assist |
| Gait | Ataxic, Steppage Gait, Retropulsion Repeated loss of balance | No high steppage gait No retropulsion | Reciprocal gain pattern No loss of balance |
| Stairs | Not attempted | 5 steps at Hand Hold Assist x 2 Reciprocal gait pattern | 16 steps at Stand by Assist Reciprocal gait pattern |
| Upper and Lower Body Dressing | Max Assist to Dependent | Mod Assist | Min Assist |
| Speech | Significant Apraxia Significant Dysarthria | Moderate Apraxia Mild Dysarthria | Mild Apraxia Minimal Dysarthria |
| Diet | NPO, NG tube in place | Soft Diet with Thin Liquids | Regular with Thin Liquids |

Discussion

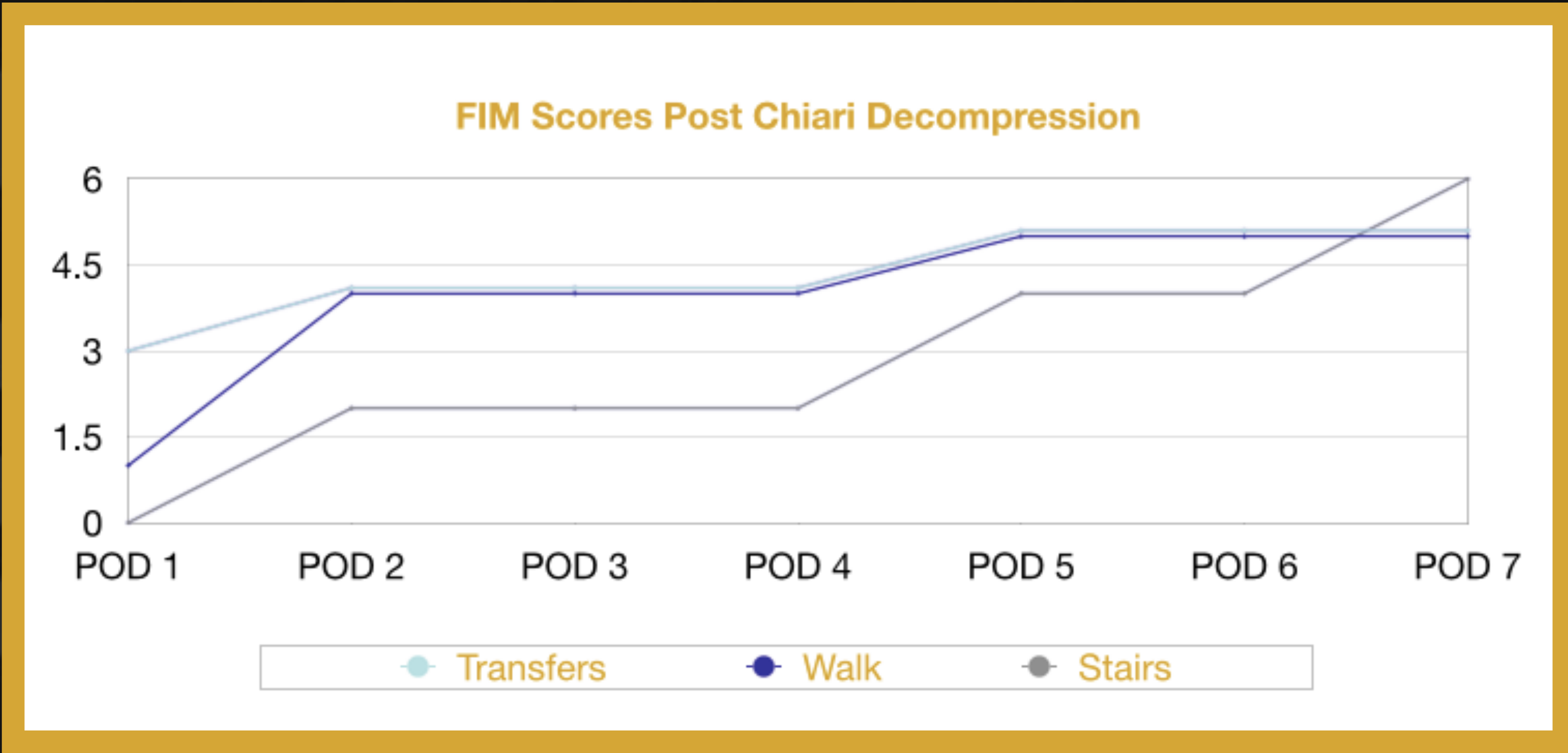
- Chiari malformations are a relatively common occurrence with an incidence of 1 per 1000 births.
- There are 4 subtypes of Chiari Malformation, each progressing in amount of cerebellum/brainstem herniations and symptom severity:
- Chiari Malformation Type 1:
 - Occurs when the cerebellar tonsils herniate 5 mm or more beneath the foramen magnum into the cervical spinal canal. (1,2,3,4)
 - The most common form, usually presents in adolescence or adulthood.
 - Generally asymptomatic, if present symptom onset is often insidious.
 - Most common presenting symptom: Nuchal or occipital pain or headache due to meningeal irritation. (1,4)
 - Symptoms: headache/neck pain, drop attacks, spasticity, dizziness, balanced problems, double/blurred vision, photosensitivity, upper extremity (UE) weakness, loss of pain/temp sensation in torso/UE. (2,3)
 - Often associated with Hydrocephalus/ Syringomyelia/Hydromyelia.
 - Prevalence of hydrocephalus associated with CM-I is approximately 10 percent. (4)
 - Frequency of spinal cavitations (syringomyelia, hydromyelia or syringohydromyelia) varies between 40 and 75%. (4)
- This displacement of cerebellar tonsils may block the normal pulsations of CSF between the spinal canal and the intracranial space. (2)
- There is no direct correlation between how low the tonsils are lying and clinical severity.
- This patient's presentation of acute ataxia, incontinence, weakness, dysphagia and dysarthria are atypical presenting symptoms for a Type 1 Arnold Chiari Malformation.
- Her concurrent adenoviral upper respiratory infection and HSV encephalitis masked a severe Chiari Crisis needing urgent surgery.

Conclusion

- This case reinforces the need for clinicians to be vigilant about rare presentations of common pathologies and emphasizes the importance of ongoing surveillance during inpatient rehabilitation.
- Marked functional improvements can follow Chiari decompression and avert further functional decompensation from brain damage.

References

- <https://www.ninds.nih.gov/Disorders/All-Disorders/Chiari-Malformation-Information-Page>
- <https://www.aans.org/Patients/Neurosurgical-Conditions-and-Treatments/Chiari-Malformation>
- <https://rarediseases.org/rare-diseases/chiari-malformations/>
- https://www.uptodate.com/contents/chiari-malformations?search=chiari%20malformation&source=search_result&selectedTitle=1~118&usage_type=default&display_rank=1





Avascular Necrosis of Bilateral Femoral Heads Following Multiple Short-Term Steroid Burst Treatments: A Case Report.



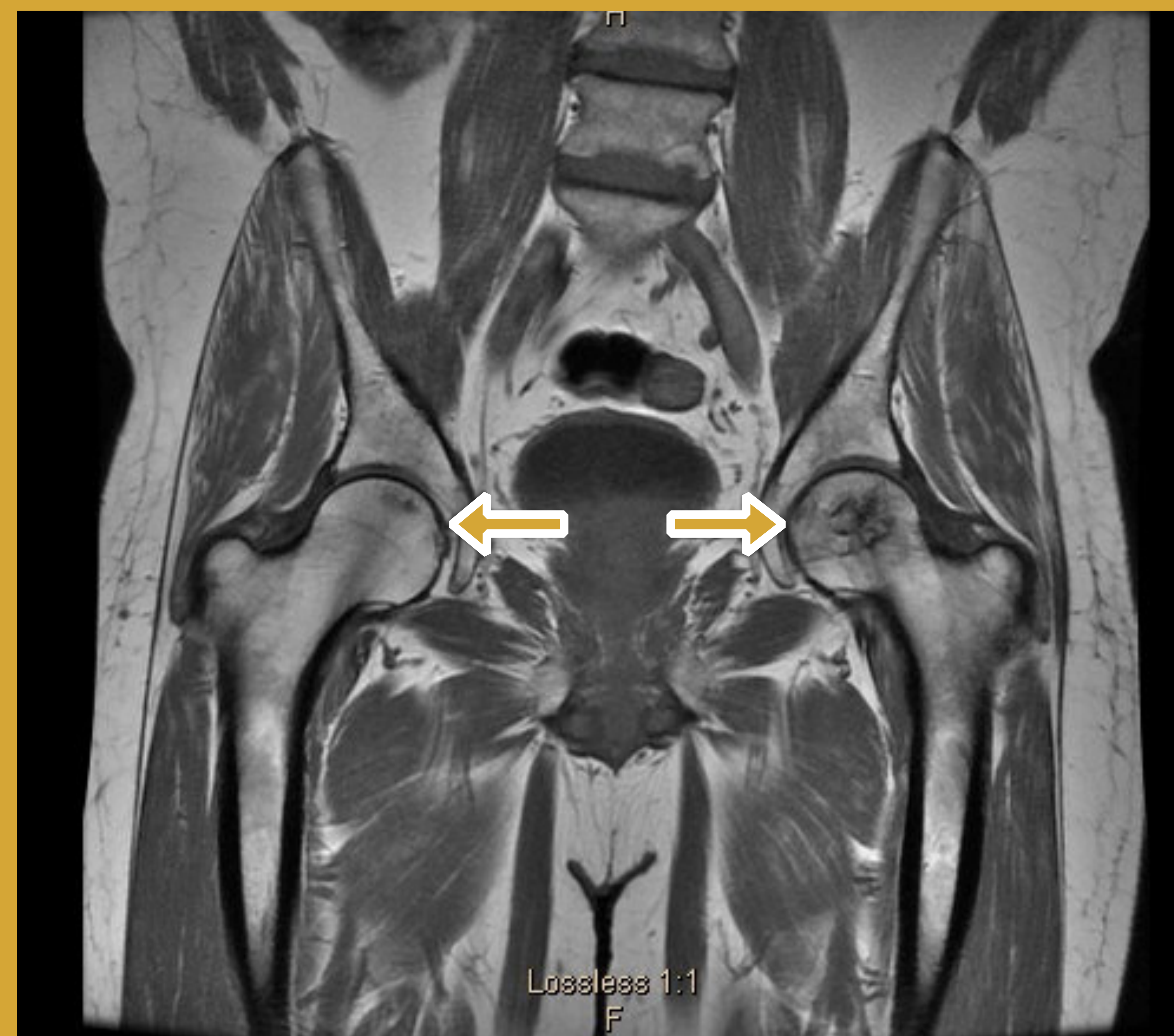
Katherine Caldwell, MS-4, Rachael Brashears DO, MBA, and Nicholas Madaffer, DO
Department of Physical Medicine and Rehabilitation
University of Missouri Healthcare, Columbia, MO

Case Description

- A 49-year-old male presented with chronic lower back and bilateral hip pain that did not respond to a recent single Medrol Dosepak.
- Sacroiliac joint (SIJ) pain was diagnosed and he underwent fluoroscopy-guided right SIJ steroid injection.
- The patient reported significant pain relief and subsequently underwent bilateral SIJ steroid injections four months later and repeated them again three months after that.
- At follow-up, the patient reported continued pain and was diagnosed with left piriformis syndrome.
- Physical therapy and a muscle relaxant were prescribed in conjunction with an ultrasound-guided steroid injection into the left piriformis.
- A few days later, the patient presented to the emergency department with acute, severe left hip pain.
- Pelvic CT revealed bilateral avascular necrosis (AVN) of the femoral heads, more prominent on the left. MRI confirmed avascular necrosis of bilateral femoral head and was also concerning for left sacroiliitis and was unable to rule out infection.
- Patient was sent to interventional radiology for a left sacroiliac joint biopsy. Initial pathology was read as normal but later addended with evidence of acute and chronic inflammation.
- A tissue culture initially had no growth but after a week revealed rare coagulase negative staphylococcus that was resistant to penicillin.
- In the meantime, the Patient was evaluated by Rheumatology who determined it was unlikely that patient had an inflammatory or reactive arthritis.
- Patient then returned to orthopedics for surgical intervention.

Results

- Patient received a surgical core decompression of his left hip by orthopedic surgery.
- This surgical procedure involved drilling a small hole into the femoral head, scraping out the damaged tissue, and replacing it with a synthetic bone graft.
- He was seen in follow up 6 weeks later and reported 95-99% pain relief.
- Patient was instructed by his Orthopedic doctor not to pursue any future steroid injections.
- He was later referred to interventional pain management for continued low back pain where he received multilevel radiofrequency ablations, including bilateral sacroiliac joints, with significant pain reduction.



MRI Hip and Pelvis

There is bilateral femoral head avascular necrosis, left greater than right. On the left, the avascular necrosis involves approximately 80% of the weight bearing articular surface. On the right, the avascular necrosis involves 10-20% of the articular surface. There is no joint effusion, synovitis, or articular surface collapse.

| Date of Service | Procedure | Steroid Dose |
|-----------------|------------------------------------|--------------------------|
| 11/29/2016 | Oral Medrol Dosepak | 84 mg Methylprednisolone |
| 12/29/2016 | Right SI Joint Injection | 40 mg Kenalog |
| 04/05/2017 | Bilateral SI Joint Injections | 80 mg Kenalog |
| 07/17/2107 | Bilateral SI Joint Injections | 80 mg Kenalog |
| 09/08/2017 | Piriformis Trigger Point Injection | 40 mg Kenalog |

References

- 1) <https://www.ncbi.nlm.nih.gov/pmc/articles/PMC3712793/>
- 2) <https://www.ncbi.nlm.nih.gov/pubmed/?term=avascular+necrosis++medrol+dose+pack>
- 3) Yamamoto T, Schneider R, Iwamoto Y, Bullough PG. Rapid destruction of the femoral head after a single intraarticular injection of corticosteroid into the hip joint. J Rheumatol. 2006;33:1701-1704. [PubMed]

Discussion

- AVN of the hip occurs when the blood supply to the femoral head is interrupted, resulting in deterioration of the bone and ultimately collapse of the femoral head.
- Steroids, routinely prescribed for inflammatory and acute pain conditions, are generally considered to be safe.
- Glucocorticoid-induced osteocyte apoptosis leading to AVN is known to occur with chronic oral glucocorticoids, with an incidence of 9-40% (1).
- A population based study of 24 million patients found a very small, but statistically significant, increased risk of AVN following a single methylprednisolone taper pack (MTP) (2):
 - Compared with the 0.083% incidence of AVN in the control group that had never been prescribed an MTP, the relative risk of AVN after the prescription of a single MTP was 1.591 and after multiple MTPs was 2.763 (2).
 - There was a statistically significant difference between cohorts ($P < .001$) (2).
 - It concluded that short-term, low-dose oral corticosteroid administration may be associated with an increased incidence of AVN when compared with patients who have never been prescribed a steroid product (2).
- A temporal association between administration of steroid product and incidence of AVN has not been well established in the literature.
- AVN has been noted in just weeks to months after intra-articular injection of cumulative doses of 80-160 mg of methylprednisolone; however, this was a local reaction only affecting the joint the steroid was injected into (3).
- AVN has not previously been reported as a complication of intra-articular sacroiliac joint steroid injections.

Conclusion

- This patient's case was complicated by the fact that he received oral, intra-articular, and intra-muscular glucocorticoids; thus, his resulting AVN could be secondary to any single form of steroid or, more likely, a result of their cumulative effect.
- This case report details a case of femoral head AVN following multiple short term steroid bursts, which reinforces the need for clinicians to be vigilant about monitoring for side effects of medications and potential procedural complications.
- It also identifies AVN of the femoral head as a risk of repeated short-term steroid burst treatments and possibly of sacroiliac joint steroid injections.